

CASE REPORT

Tuberculous Dactylitis in a 20 Year Old – A Rare Case Report

Shefali Goyal^{1*}, Ambica C¹, Anita P. Javalgi¹, S.U. Arakeri¹

¹Department of Pathology, BLDEU's Shri B. M. Patil Medical College, Hospital & Research Centre, Vijayapura-586103 (Karnataka) India

Abstract:

Tuberculosis is an infectious disease caused by *Mycobacterium tuberculosis* and manifested by formation of tubercles and caseous necrosis in tissues. Tuberculous spondylitis is the most typical form of disease in the musculoskeletal system. Tubercular dactylitis is the tuberculous infection of metacarpal, metatarsal and phalanges and is uncommon. Tuberculous granuloma results in spindle shaped expansion of the short tubular bones, so it is also called as Spina Ventosa (Spina=thorn, Ventosa=full of air). We present a case of 20 year old female with an isolated swelling in the right thumb of 3 months duration.

Keywords: Dactylitis, Granuloma, Spina ventosa, Tuberculosis

Introduction:

Osteo-articular tuberculosis involving short tubular bones of hands and feet such as metacarpals, metatarsals, phalanges is rare [1]. It is more commonly seen in younger population with 85% cases seen in children less than 6 years and accounts for 0.65% to 6.9% of all forms of tuberculous cases in children [1-3]. Diagnosis of tubercular dactylitis is often delayed due to paucibacillary nature of osseous tuberculosis. Tuberculosis of hand usually begins as tenosynovitis and eventually spreads to bones and joints [2]. Tuberculous Dactylitis (TD) can present without evidence of tuberculosis in any other part of the body or without constitutional symptoms, further adding to diagnostic difficulty [1]. The most striking and often worrisome feature is the delay between onset of symptoms and correct diagnosis [4].

Case Report:

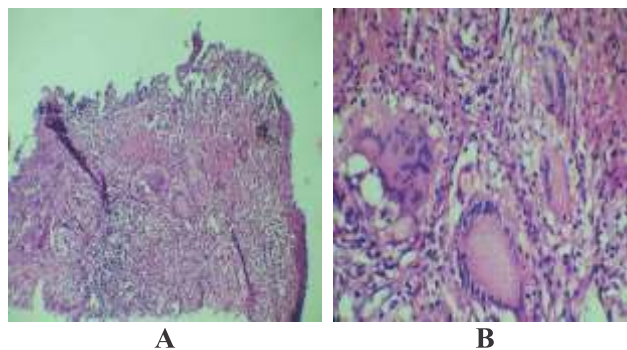
A 20 year old female presented with pain and swelling of the right thumb since last 3 months. The swelling was initially small and was gradually increasing in size. There was no history of trauma or exposure to tuberculosis.

On examination, a 3x3cm swelling was seen over the first interphalangeal joint of right thumb. The swelling was firm, tender and local temperature was slightly raised. Patient also gave history of painful and restricted movements of joints. Radiograph of the right thumb showed bony irregularity in the lower end of the distal phalynx with increased joint space and soft tissue swelling. Chest radiograph was normal (Fig.1). Clinically diagnosis of tumor/dactylitis was suspected. Excision biopsy of the lesion was done and the specimen was sent for histopathological examination. Macroscopic examination revealed multiple pale pink tissue bits, largest measuring 2x1x0.5cms and smallest measuring 0.2x0.2x 0.1cms. All the bits received were embedded.

Microscopy revealed many granulomas comprised of central caseating necrosis surrounded by many foreign body type giant cells and Langhans type giant cells were seen suggestive of tuberculosis (Fig.2). Endarteritis, histiocytic hyperplasia and fungal elements were not seen. Ziehl Neelson stain for acid fast bacilli was negative. Erythrocyte Sedimentation Rate (ESR) was 80mm at the end of one hour.

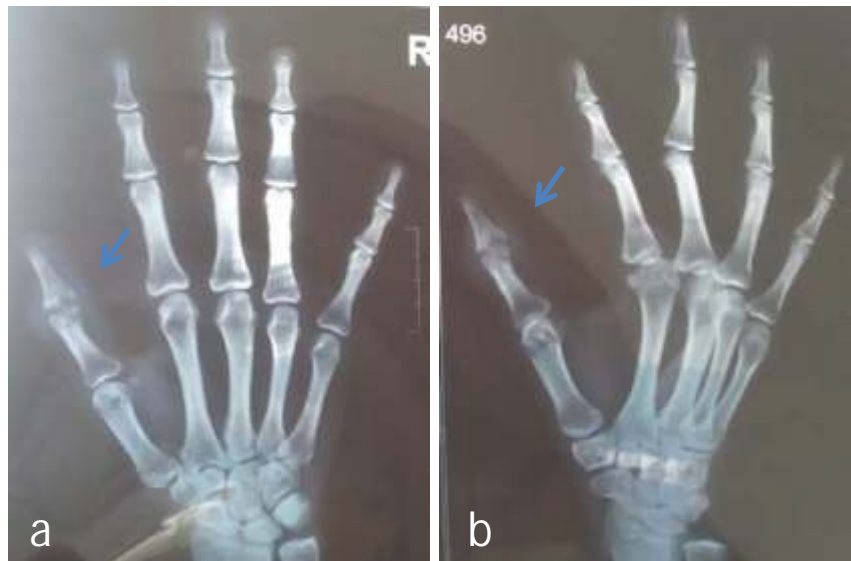

Fig. 1: Bony Irregularity in the Lower End of Distal Phalanx with Increased Joint Space and Soft Tissue Swelling A) Anteroposterior View B) Lateral View



**Fig. 2: A) Granuloma with Central Caseous Necrosis (H and E 40X)
B) Foreign Body and Langhans Type of Giant Cell (H and E 400X)**

Discussion:

Symptoms of skeletal tubercular infection occur within 1-3 years after initial infection of tuberculosis [2]. Extrapulmonary tuberculosis progresses to skeletal tuberculosis in 1 to 5% of cases [5]. The factors for the diagnostic delay of TD are attributed to the paucibacillary nature of the lesion, insidious onset, slow progression, non-specific clinical manifestations, occurrence of disease in the absence of pulmonary tuberculosis, non-specific radiographic findings, lack of rapid

microbiological diagnostic method, occasional inconclusive microbiological and histopathological findings and lack of awareness of TD among treating physicians and surgeons [1]. In the present case also the lesion was slow growing with non-specific clinical presentation of pain and swelling. There was no evidence of pulmonary tuberculosis radiologically or clinically. Ziehl Neelson stain was negative in the present case, may be due to the paucibacillary

lesion. The radiographic feature of cystic expansion of short tubular bones has led to the name of spina ventosa being given to tuberculous dactylitis of the short bones of the hands. Periosteal reaction and sequestra are not common but may occur. Sclerosis may be seen in long standing cases [6, 2]. In the present case, cystic expansion of the bone, periosteal reaction and sequestra were not seen. The first inoculum of infection is lodged in the centre of the marrow cavity and the interior of the short tubular bone is converted gradually into a tubercular granuloma [6, 2].

TD needs to be differentiated clinically and radiologically from chronic pyogenic osteomyelitis, syphilitic dactylitis, sarcoidosis, brucellosis, mycotic infection and neoplastic conditions with lytic lesions such as enchondroma, giant cell tumour, chondroblastoma, osteoid

osteoma, aneurysmal bone cyst and paget's disease [2]. Based on histopathological findings antitubercular drugs were started. Patient responded well to antitubercular treatment.

Conclusion:

TD is an unusual form of bone tuberculosis. The clinical presentation and imaging studies are non-specific. Thus, the diagnosis of TD should always be kept in mind while dealing with pathology of short tubular bones of hand and feet as it is often missed because of absence of stigmata of tuberculosis in other parts of the body especially lung. Tissue pathological and microbiological examination represents the hallmark of diagnosis. Any delay in diagnosis and treatment of TD will likely decrease the chances of good functional outcome.

References

1. Ali N, Bhat A, Fatima A, Muzzafar K, Latoo IA, Singh R. Tuberculous dactylitis: A case series and review of literature. *J Pioneer Med Sci* 2014; 4(4):184-90.
2. Panchonia A, Kulkarni CV, Mehar R, Mandwariya S. Isolated tuberculosis dactylitis (Spina Ventosa) in a 9 year old boy-A rare entity. *IJBAMS* 2012; 2(2):52-5.
3. Khanna V, Vaishya R, Vijay V, Vaibhav V. Spina ventosa in an 18 year old. *Apollo Medicine* 2014; 11(3): 239-40.
4. Harinatha S, Raghunath N, Petkar K, Harinatha S. Localized tubercular swelling in the hand masquerading as a ganglion-A rare case report. *Our Dermatol Online* 2012; 3(4):353-4.
5. Aisenberg G. Tuberculous Dactylitis: An unusual finding demanding invasive diagnosis. *J Clin Case Rep* 2014; 4:389.
6. Jindal MK. Tuberculous dactylitis presenting as a pathological fracture a case report. *Webmed Central Orthopaedics* 2015; 6(10):WMC004994.

***Author for Correspondence:** Dr. Shefali Goyal, Department of Pathology, BLDEU's Shri B. M. Patil Medical College, Hospital & Research Centre, Vijayapura-586103 (Karnataka) India
Email: goyalshefali07@gmail.com Cell: 09916481501